

Efficacy of a 3D Electrospun Synthetic Polymer Matrix on Hard-to-Heal Wounds

C. JAKE LAMBERT, JR, MD, FACS, CWSP¹
SURGEON

KRISTEN A. ECKERT, MPHIL³
SENIOR WRITER/EDITOR

FRANK AVILES, JR, PT, CWS, FACCWS, CLT-LANA,
ALM, AWCC²
DIRECTOR

MATTHEW GAROUFALIS, DPM, FASPS, FACPM, CWS⁴
MEDICAL DIRECTOR

RICHARD A. SCHILLING, DPM, FACFAS⁵
PODIATRIC PHYSICIAN

¹CARDIOTHORACIC & ENDOVASCULAR MEDICINE, BOND CLINIC PA, WINTER HAVEN, FLORIDA

²LYMPHATIC AND WOUND HEALING SERVICES, HYPERBARIC PHYSICIANS OF GEORGIA, CUMMING, GEORGIA

³STRATEGIC SOLUTIONS, INC., BOZEMAN, MONTANA

⁴PROFESSIONAL FOOT CARE SPECIALISTS, PC, CHICAGO, ILLINOIS

⁵ABC PODIATRY, COLUMBUS, OHIO

ABSTRACT

Introduction: The aim of this study was to evaluate the efficacy of a 3D electrospun synthetic polymer matrix (3DESPM) on hard-to-heal wounds.

Materials and Methods: This prospective case series took place at four sites. The primary endpoints were the percentage area reduction (PAR) in wound area at four and eight weeks. Secondary endpoints included time to heal (Kaplan-Meier analysis) and the proportion of healed wounds at 12 weeks. After applying 3DESPM, the physician applied sterile saline, as appropriate, to adhere the matrix to the wound bed and facilitate the polymer degradation process. A nonadherent dressing, a secondary dressing, and additional bandages (as needed) were then applied. The physician left the product on the wound until complete degradation was observed, as appropriate, and reapplied, as appropriate. Combination advanced therapies were applied, per physician discretion.

Results: Thirty-eight patients (mean age: 64.3 years [SD: 17.6]) with 50 wounds (35 chronic, 70%) participated. The mean number of comorbidities per patient was 4.4 (2.3). All wounds received 3DESPM; 12 wounds (24%) received combination therapies; and 38 wounds (76%) completed the study. The mean (SD) PAR at four and eight weeks was 67.6% (38%) and 80% (35%), respectively. Thirty-three wounds (66%) healed at 12 weeks. The Kaplan-Meier mean time to heal for all wounds was 49.0 days (95% confidence interval: 41.3–56.7).

Conclusions: In a complex patient population with severe comorbidities and heterogeneous wounds, 3DESPM appeared to accelerate the stalled healing process to contribute to wound closure. Further investigation of 3DESPM on a larger patient population and in a controlled setting is pending.

INTRODUCTION

The annual cost of wound care for all wound types among Medicare patients may reach nearly \$97 billion.¹ Chronic wounds affect more than 6.7 million patients in the United States (US), while 17.2 million hospital visits are due to acute wounds.¹⁻⁴ Wounds normally heal in a four-stage process involving hemostasis, inflammation, proliferation, and remodeling. Delayed healing occurs when the inflammatory or proliferative stage is stalled, with chronicity generally determined after four to eight weeks of failure to heal.⁵ Skin grafts, including cellular and/or tissue-based products (CTPs), are widely used to treat refractory wounds, but they carry the risk of immune rejection and other morbidities. While protective, antimicrobial, and moist advanced wound dressings risk adhesion damage to the wound bed and high costs.⁶⁻¹¹ Although recent systematic reviews of the use of skin grafts and substitutes on chronic wounds have supported their beneficial use on diabetic foot ulcers (DFUs),¹²⁻¹⁴ the evidence for their use on venous leg ulcers (VLUs) is inconclusive due to the very small size of trials.¹² As we face an aging population, in addition to the rising toll of diabetes and obesity, wound care is becoming a public health crisis that urgently requires cost-effective treatments that are proven to accelerate the healing process and facilitate wound closure. The optimal skin substitute and wound dressing for healing chronic wounds has been

described as one that transitions the chronic wound to the acute state, is non-immunogenic, and is a bioresorbable scaffold that promotes cellular activity, mimics the extracellular matrix (ECM), promotes granulation, and manages free radicals.^{6,15}

In native, normal skin, dermal fibroblasts produce collagen that comprises the ECM and serves as the biomechanical structure for reepithelialization in wound healing. Emerging electrospun synthetic technologies are being considered among the most efficient wound dressings because they are bioengineered to structurally mimic native ECM. They also have a porous matrix with a high surface-area-to-volume ratio that facilitates homeostasis, cell adhesion, migration, proliferation, and exudate management.^{5,6,16-18}

Electrospinning is a manufacturing process that uses a high voltage to charge a polymer solution until a Taylor cone is formed and the electrostatic forces overcome the surface tension, ejecting a liquid jet toward a collector.^{5,18,19} The solvent evaporates in midair and the resulting fibrous and microporous scaffold mimics the microstructure of natural ECM to create an ideal wound dressing for tissue regeneration.^{5,18,20,21} Despite the consensus that electrospun polymer nanofibrous matrices and their regenerative properties could be used to heal complex, refractory wounds, until now, their clinical impact has yet to be evaluated.^{5,18,22-26}

The US Food and Drug Administration (FDA) has cleared a novel, advanced 3D electrospun synthetic polymer matrix

(3DESPM) for use in the management of chronic and acute, partial, and full-thickness wounds including: pressure injuries (PIs), venous ulcers, diabetic ulcers, arterial ulcers, tunneled/undermined wounds, surgical wounds, trauma wounds, and second-degree burns. In this multicenter case series, the efficacy of 3DESPM on the management of hard-to-heal wounds of various etiologies on complex patients was evaluated.

MATERIALS AND METHODS

This real-world, prospective case series evaluated the effect of 3DESPM on patients with chronic or hard-to-heal wounds at four US-based sites, including a regional hospital (site #1), two private practices (sites #2 and #3), and an outpatient clinic (site #4). For this exploratory study, there was no sample size calculation or predetermined target. The primary endpoints were the percentage area reduction (PAR) in wound area at four and eight weeks. Secondary endpoints included PAR at 12 weeks, time to heal at 12 weeks, and the total proportion of healed wounds (defined as 100% reepithelialization, without exudate, drainage, or dressing, confirmed at two visits two weeks apart) at 12 weeks. The number of applications used for wound treatment was also analyzed.

The study sponsor (RenovoDerm[®], Dublin, Ohio) provided sites with 3DESPM and instructed physicians to use it on patients with hard-to-heal wounds. Patients with multiple wounds that were appropriate for 3DESPM treatment had each wound included in the study. All sites required that patients had good nutritional management and demonstrated adequate perfusion and good blood flow based on palpable pulses and vascular studies. All patients with diabetes had to have their hemoglobin A1C controlled (<10% to <13%, depending on the study site protocol) for study inclusion. Site #2 was instructed by the sponsor to enroll patients with DFUs only. Site #2 included patients with chronic DFUs that had minimal eschar and no infection, which failed to heal after four weeks of standard of care (including complex wound dressings) and who worked toward glucose management and would be compliant during the study. Sites #1, #3, and #4 included challenging patients with wounds of various etiologies. At site #4, which treated arterial/vascular wounds with 3DESPM, patients with




Figure 1. A physician holds a matrix example of 3D electrospun synthetic polymer matrix (3DESPM). The circle on the left shows a scanning electron microscope image of 3DESPM nanofibers, which have a pore size of approximately 5µm.

ischemia (defined as an ankle-brachial index <0.7 or by Doppler study showing significant arterial disease) were eligible for study enrollment after undergoing revascularization.

Physicians screened all patients and selected those who they thought would be compliant with the study procedure and follow up. Patients provided verbal or written informed consent to participate in this study and to publish their photographs. At each screening visit, physicians performed a comprehensive physical examination, recorded medical and medication history, confirmed vascular status, and provided standard of care. Standard of care included a complete wound and infection assessment, wound cleansing and debridement (as necessary), moist dressings, offloading (for DFUs and PIs, included controlled ankle motion walkers and total contact casting), multilayer compression for VLUs, and implementing an air mattress turning schedule for PIs.

Study product and procedure

PHOENIX™ Wound Matrix (RenovoDerm®) is a conformable, nonwoven, fibrous, 3D matrix composed of two synthetic polymers: poly(lactide-co-caprolactone) and polyglycolic acid, which are bioresorbed via hydrolysis releasing α -hydroxy and fatty acids into the local wound environment. Nanofiber Solutions, LLC (Dublin, Ohio) developed the advanced electrospinning process used to manufacture 3DESPM, and this technology is also currently utilized for an implantable rotator cuff repair product (Rotium™ Bioresorbable Wick, Atreon Orthopedics, Dublin, Ohio).²⁷ Figure 1 depicts 3DESPM, which is supplied as a sterile, single-use device that is stored in a cool and dry place. The 3DESPM is available as a fenestrated or nonfenestrated matrix in seven different sizes: 1.6cm diameter disc, 1.5 x 2cm, 4 x 3cm, 5 x 2.5cm, 5 x 5cm, 10 x 10cm, and 20 x 10cm.

After patients consented and were enrolled in the study, most wounds were treated immediately with 3DESPM. After debriding and cleansing the wound, the physician trimmed the 3DESPM so that the edges of the product matched the edges of the wound bed. To accommodate for drainage and obtain a better surface area, the physician could fenestrate the 3DESPM. The matrix was gently applied to the wound bed, ensuring that it came in intimate contact with the base

Table I
Patient demographics and clinical characteristics (n=38)

Variable	
Patient age (years)	64.3 (17.6)
Sex	
Male	25 (65.8%)
Female	13 (34.2%)
Race/ethnicity	
White/non-Hispanic	30 (78.9%)
Black/African-American	5 (13.2%)
Hispanic	3 (7.9%)
Comorbidity count	4.4 (2.3)
Body mass index >30	20 (52.6%)
Diabetes	27 (71.1%)
Hypertension	21 (55.3%)
Vascular insufficiency	19 (50.0%)
Ischemia	4 (10.5%)
Peripheral arterial disease	19 (50.0%)
Peripheral vascular disease	2 (5.3%)
Any other heart disease	3 (7.9%)
Hyperlipidemia	2 (5.3%)
Renal disease	3 (7.9%)
Smoker	2 (5.3%)
Peripheral neuropathy	16 (42.1%)
Prior amputation	6 (15.8%)
Note: continuous variables are reported as means (SD) and categorical variables as counts (percentage).	

tissue. The physician then applied sterile saline, as necessary, to adhere the matrix to the wound bed and to activate the polymer degradation process via hydrolysis. The product could be fixated to the wound with reinforced adhesive skin closure (Steri-Strip™, 3M Company, St. Paul, Minnesota), per the physician's discretion. A nonadherent dressing (Adaptic™, 3M Company, St. Paul, Minnesota) was placed over the 3DESPM to bolster it to the wound bed, followed by a secondary dressing and additional bandages, as needed. Sites #1 and #4 sometimes used negative pressure wound therapy (NPWT) to bolster the product, especially when managing PIs. The product was left on the wound bed until complete degradation was observed, unless debridement was deemed necessary at weekly visits. Once the product was completely degraded, a new 3DESPM was applied to the wound, as clinically appropriate.

Weekly treatment visits were similar

to the screening visit and occurred up to 12 weeks. The frequency of 3DESPM application varied by site, with site #4 reapplying weekly following a weekly debridement, while sites #1–3 tried to leave the product undisturbed for at least 14 days. When the product was left undisturbed, the physician assessed for matrix take and moisture management. The schedule for changing dressings also varied from site to site from weekly to three times weekly, depending on whether home healthcare was used in between visits (at sites #1 and #3). After healing was first observed, the subject returned for a follow-up visit to confirm healing at least two weeks later. Some subjects had additional follow-up visits because they returned for additional care not related to the study wound. If a wound deteriorated, such as increased in area by at least 30% or suddenly had tunneling, then treatment with 3DESPM was stopped, and the subject was withdrawn from the study.

Table II
Wound characteristics (n=50)

Variable	
Wound type	
Venous leg ulcer	20 (40%)
Diabetic foot ulcer	15 (30%)
Pressure injury	5 (10%)
Trauma	3 (6%)
Other	3 (6%)
Arterial	2 (4%)
Surgical	2 (4.0%)
Number of wounds per patient (n=38)	
1	32 (84%)
2	2 (5%)
3	2 (5%)
4	2 (5%)
Wound area (cm²)	
	10.2 (1.8)
Wound age (weeks)	
	19.1 (11.0)
Wound age >12 weeks	
	23 (46%)
Chronic wound	
	35 (70%)
Wound infection	
	23 (46%)
Osteomyelitis	
	7 (14%)

Note: continuous variables are reported as means (SD) and categorical variables as counts (percentage). 3DESPM = three-dimensional electrospun synthetic polymer matrix.

Data collection and statistical analysis

Investigators collected deidentified data into a master Excel® database (Microsoft Corporation, Redmond, Washington) and used PASW 27 to perform statistical analysis. Missing data were addressed with the last observation carried forward principle. Continuous variables were presented as means and standard deviations (SDs). Categorical variables were summarized as counts and proportions or percentages. The PAR for the index wound at X weeks was calculated as $((A_1 - A_{xw}) / A_1) * 100$, where A_1 is the area of the index wound at randomization and A_{xw} the area at X weeks. A Kaplan-Meier analysis was performed to evaluate the time to heal.

RESULTS

Screening and enrollment began on February 1, 2019, and the study ended with the last follow-up visit on June 14, 2021. Thirty-eight patients (65.8% male; 78.9% White) with 50 wounds were screened and all were enrolled in this study (Table I). They had a mean (SD) age of 64.3 (17.6) years and a mean number of comorbidities of 4.4 (2.3). The majority of patients had diabetes, hypertension, and obesity; half of the patients had vascular insufficiency and peripheral arterial disease (Table I). Most patients (n=32, 84%) had only one wound. The most frequently occurring wound type was VLU (n=20, 40%), followed by DFUs (n=15, 30%, Table II). Among the three “other” wound types, there was a case of chronic pseudoepitheliomatous hyperplasia on the left lateral malleolus, a chronic pilonidal cyst, and a case of chronic gout on the right elbow.

Most wounds were located on the lower extremities (n=43, 86%). The wounds were substantial with a mean baseline area of 10.2cm². The majority were chronic (n=35, 70%), with nearly half (n=23) having a duration longer than 12 weeks.

All 50 wounds received 3DESPM applications in an outpatient setting, except for the first three patients’ wounds enrolled at site #1 where the site investigator first evaluated 3DESPM in a controlled, in-patient setting. Twelve wounds (24%) received 3DESPM in combination with other advanced therapies, with NPWT used adjunctively during 3DESPM application on 10 wounds (20%). Two wounds (4%) received

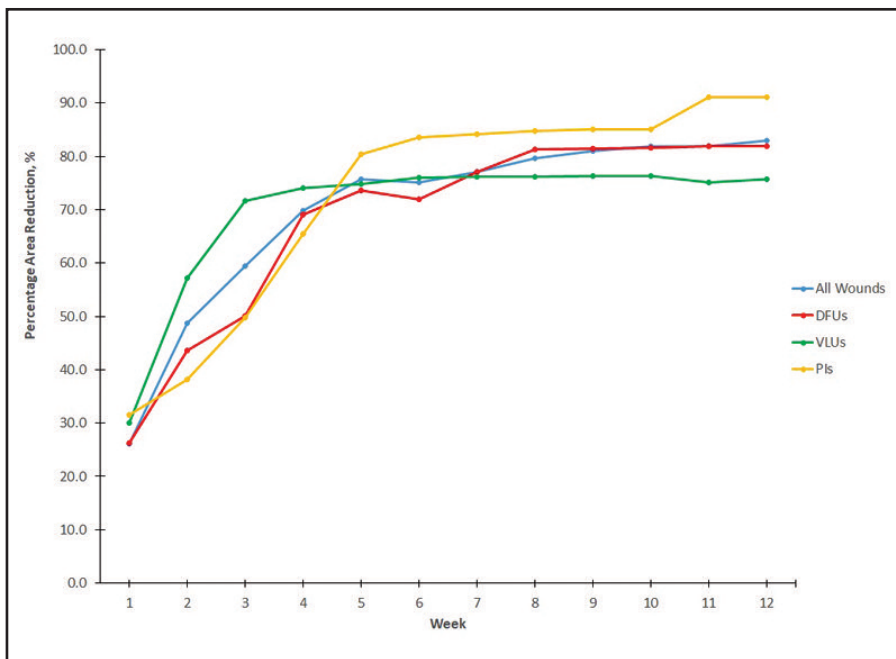


Figure 2. Mean PAR for all wounds, VLUs, DFUs, and PIs up to 12 weeks.

hyperbaric oxygen therapy (HBOT) and three wounds (6%) received collagen dressings. Twelve wounds (24%) in nine patients (24%) did not complete the study; three patients (three wounds) died as a result of underlying conditions; four wounds in four patients deteriorated; one patient (one wound) was hospitalized for treatment of their condition; and one patient with four wounds changed physicians.

The mean (SD) PAR at 4, 8, and 12 weeks for all wounds was 67.6% (38.2%), 80.1% (35.2%), and 83.2% (36.4%), respectively. Figure 2 shows the mean PAR for all wounds, VLU, DFUs, and PIs up to 12 weeks. The healing trajectory was similar for all wounds, with PIs showing a slightly improved reduction in area compared to the other wound types.

At 12 weeks, 33 (66%) wounds were completely healed, including 22 (63%) chronic wounds. In 14 wounds (28%), 3DESPM treatment was stopped early and the wounds went on to heal with standard of care. Four wounds (8%) healed with 3DESPM and the combined adjunctive use of NPWT (n=4), HBOT (n=2), and/or collagen dressings (n=1). At site #3, subject 12, wound 13 (a chronic DFU) had a two-week PAR of 60.7% following two applications of 3DESPM. Due to the early accelerated healing effect, the physician deemed treatment with 3DESPM no longer necessary and applied simpler collagen dressings at the week two visit. The wound healed two weeks later on day 28.

Figure 3 depicts the Kaplan-Meier time-to-heal curve for all wounds; their mean time to heal was 49.0 days (95% confidence interval [CI]: 41.3–56.7). Figure 4 depicts the Kaplan-Meier time-to-heal curve for chronic wounds; their mean time to heal was 53.8 days (95% CI: 45.4–62.2). The mean (SD) treatment time for unhealed wounds was 42.0 (29.8) days.

Nineteen (38%) wounds received only one application of 3DESPM; 12 (24%) received two applications; eight (16%) received three applications; and 11 (22.0%) received more than three applications.

Figures 5–8 summarizes complex cases that healed. Figure 5a–c describes a chronic PI that was treated with two applications of 3DESPM and NPWT and healed after 77 days. Figure 6a and b describes a chronic DFU that healed after 42 days of treatment with three applications of 3DESPM. Figure 7a–c describes

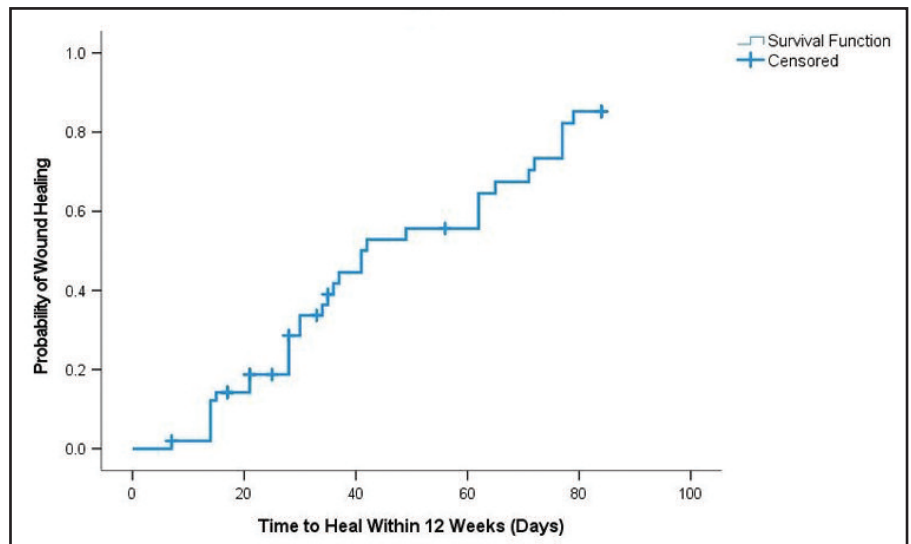


Figure 3. Kaplan-Meier time-to-heal curve for ALL wounds.

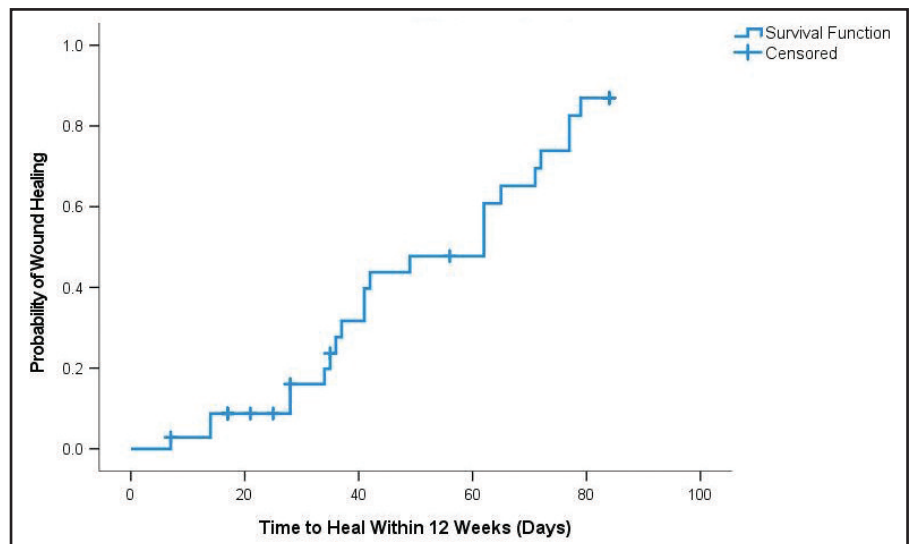


Figure 4. Kaplan-Meier time-to-heal curve for chronic wounds.

a chronic surgical wound resulting from the amputation of a toe with a DFU, which healed after five 3DESPM applications at 65 days. Figure 8a and b describes an acute VLU (the largest of 4 VLUs on the same patient), which healed after two 3DESPM applications at 30 days.

DISCUSSION

In this real-world study, 3DESPM accelerated the healing of heterogeneous, refractory wounds in a complex patient population. Previous studies reported that 50% to 60% PAR was a predictor of wound healing at 12 to 16 weeks.²⁸⁻³⁰ In this study, the baseline wound area reduced on average by an impressive two-thirds at four weeks post application, and the mean PAR increased to 80% by eight

weeks, suggesting the early healing effect of 3DESPM is efficacious. Mean PAR was similar for all wound types, with slightly higher reductions observed in PIs (Fig. 2). Closure rates at 12 weeks were similar for all wound types and chronic wounds in this study (66% vs 63%). The times to heal were also similar for all wounds and chronic wounds in this study, with wounds healing on average in less than eight weeks (Figs. 3 and 4).

The cost of skin substitutes and CTPs, compared to their clinical efficacy, has frequently come under scrutiny in recent years.³¹⁻³⁴ A main factor that drives up treatment costs is the total product cost, based on the number of applications needed. A review of data from 89,341 patients treated with bilayered skin substitute (BSS), human fibroblast-derived

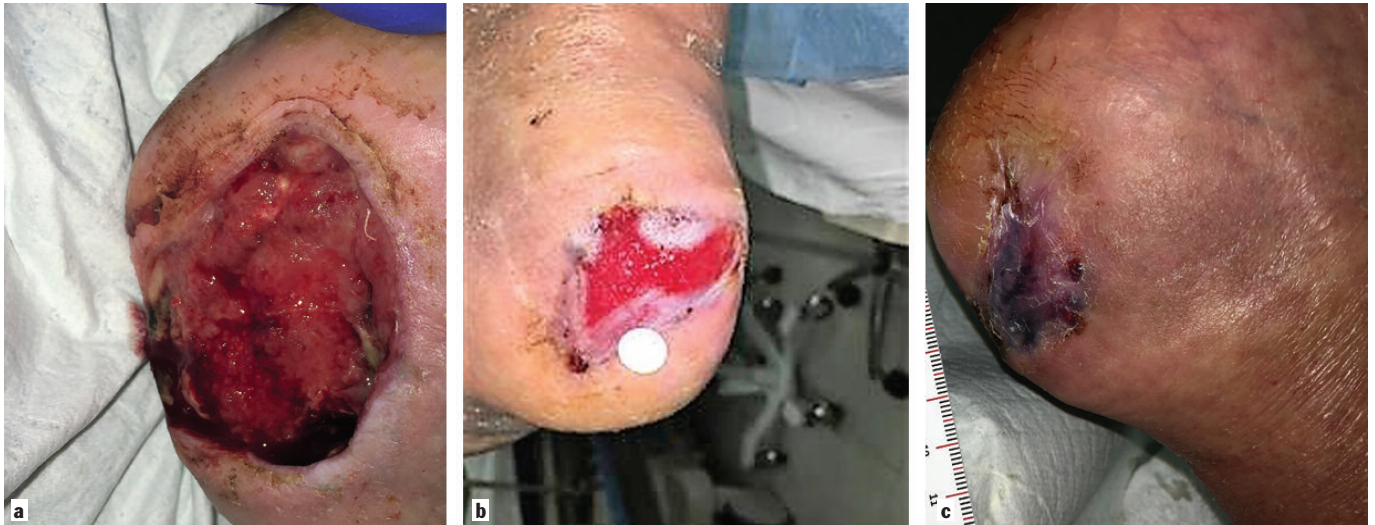

Figure 5a. A 90-year-old, White male patient (subject 2) with paraplegia presented with a chronic pressure injury (wound 2) of 18 weeks duration on the right heel at site #1. The wound is shown here at baseline measuring 11.8cm² with a 2.2cm tunnel superomedially. The wound was infected and developed osteomyelitis. After this photograph was taken, the physician surgically debrided the wound and applied the first application of 3DESMP using negative pressure wound therapy (NPWT) to fixate the matrix to the wound, per site protocols. **b)** Wound 2 is shown with a 70% reduction in wound area, measuring 3.6cm², 42 days after 3DESMP treatment began. The wound received two applications of 3DESMP at baseline and one week later; both matrices were applied using NPWT. After the second application fully degraded into the wound bed, only standard of care, including offloading and a turning schedule, was used to close the wound. **c)** Wound 2 on subject 2 is shown fully closed and healed on Day 77.

skin substitute (HFDSS), and cryopreserved human skin allograft found that at 90 days, patients treated with HFDSS received significantly more applications than those treated with the other advanced matrices (mean of three vs. two applications, $p < .05$), which likely drove up treatment costs.³⁴ A DFU randomized controlled trial (RCT) that compared BSS to dehydrated human amnion/chorion membrane reported the median number of grafts used were six and 2.5, respectively, which cost \$8,918 and \$1,517 per healed wound.³⁵ Although a product cost analysis of 3DESMP was not

performed, only two or less applications of 3DESMP were needed to treat the majority of wounds (31/50, 62%) in this study, with 38% of wounds receiving only one application. Therefore, the use of 3DESMP to treat wounds may incur potential cost savings. In this study, product availability, usage, and application procedures varied at all four sites. Thus, it will be important to compare the effectiveness of adjunctive 3DESMP to standard of care alone in a controlled setting.

The mechanism of action of 3DESMP merits further investigation. In this study, 3DESMP appeared to provide a tempo-

rary, bioresorbable scaffold in which normal cellular healing processes functioned, allowing for new tissue formation.³⁶ While human dermal fibroblasts have a pore size of 6–20 μ m,^{5,37} 3DESMP has fibers ranging 600–1,000nm in diameter; its microporous scaffold mimics native ECM. Among refractory wounds stalled in the inflammatory phase, 3DESMP accelerates the healing process by promoting cellular adhesion, infiltration, and proliferation. Via hydrolysis, 3DESMP immediately begins to naturally degrade upon placement in the wound bed, contributing α -hydroxy, caproic,

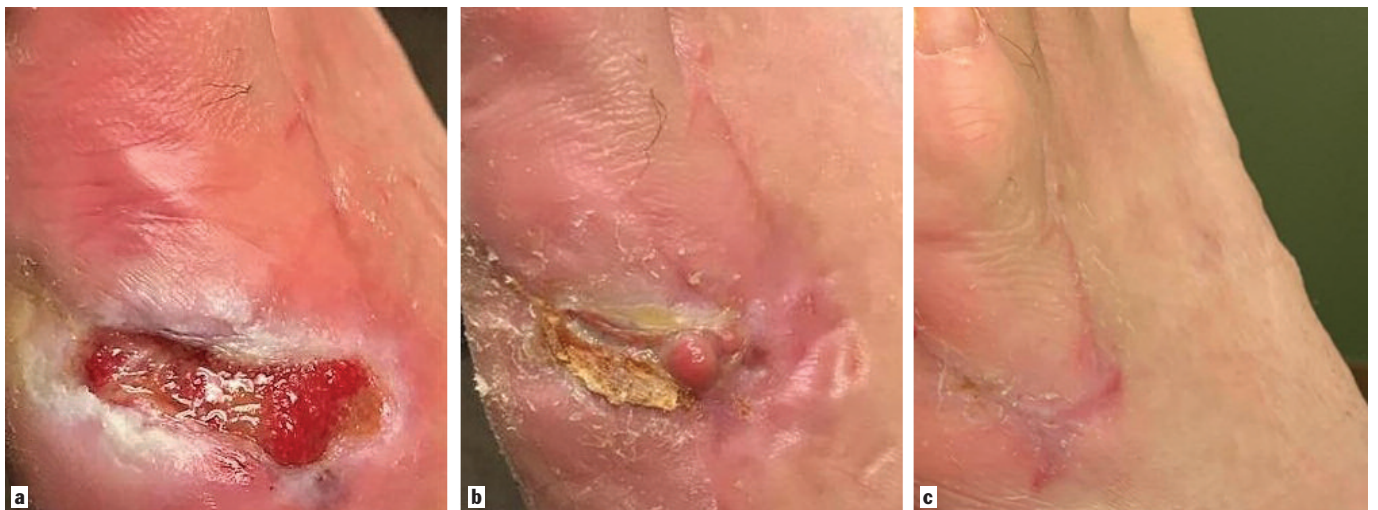

Figure 6a. A 51-year-old obese White male patient (subject 8) presented to site #2 with a chronic diabetic foot ulcer (wound 8) that measured 2.44cm². The patient had a history of diabetes, peripheral neuropathy, and hypertension. The wound formed eight weeks prior due to traumatic puncture to the lateral left foot plantar surface with subsequent osteomyelitis, necessitating an amputation of the fifth metatarsal head, followed by six weeks of intravenous antibiotics. **b)** Wound 8 is shown on day 14 after two weekly applications of 3DESMP. The wound measured 1.38cm², a 43% reduction in area. **c)** Wound 8 on subject 8 is shown healed on Day 42 after three applications of 3DESMP.

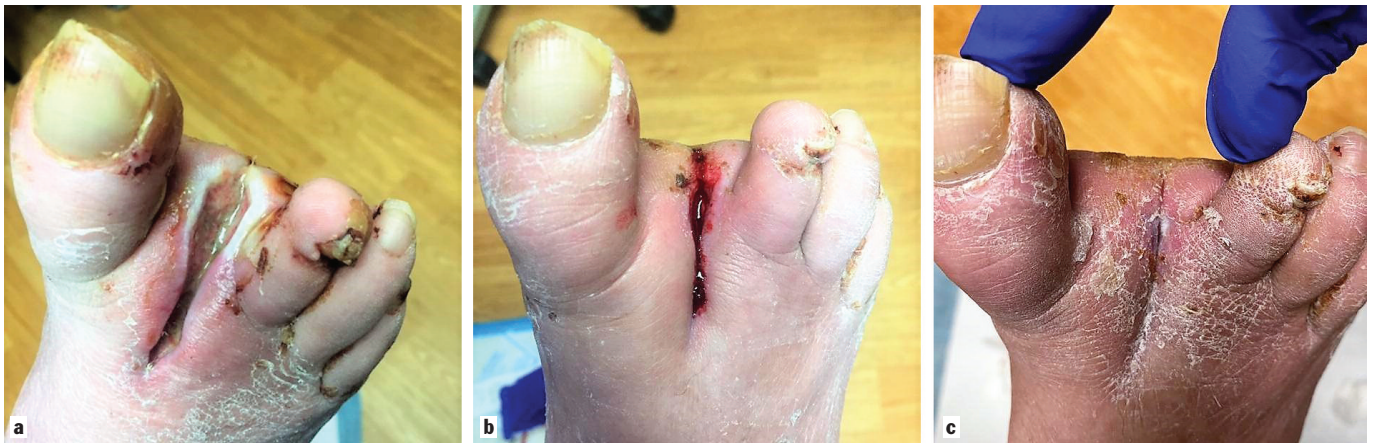

Figure 7a. A 68-year-old White male patient (Subject 15) with diabetes vascular insufficiency, ischemia, and neuropathy presented to the site #3 graft clinic with a chronic surgical wound (wound 16) of 28 weeks duration that was caused by the second ray section of a diabetic foot ulcer on the second toe of the right foot. At baseline, the stalled, nonpalpable wound measured 5.72cm² and was infected with osteomyelitis. After managing the infection, 3DES PM was applied. **b)** After 31 days of treatment with four applications of 3DES PM, the wound area reduced by 69% to 1.75cm² and blood flow was restored, as pictured. **c)** Wound 16 on subject 15 is shown closed after 65 days of treatment with five applications of 3DES PM.

and lactic acids to the local wound environment and promoting healthy tissue regeneration via the gradual regrowth of native ECM.^{36,38} Complete degradation of the temporary scaffold occurs within 7 to 14 days.

Increasing attention has been placed on the role of the microbiome in the pathogenesis of chronic wounds.³⁹⁻⁴³ Microbial colonization in an already inflammatory wound is believed to stall inflammation and result in wound chronicity. Most microorganisms cannot thrive on the acidic and dry surface of the skin, but in alkaline chronic wounds, they form a resistant biofilm.³⁹⁻⁴³ During the 3DES PM degradation process, the matrix gradually releases weakly acidic monomers (glycolic acid, lactic acid, and caproic acid) into the wound bed, lowering wound pH. A lower pH transitions the wound to a pro-healing acidic state and is protective against microbial proliferation and destructive proteases that

increase during a stalled inflammatory response.⁴²⁻⁴⁴ Therefore, a therapy, such as 3DES PM, that supports pH modulation and reduces the wound's pH levels, has been proposed to be beneficial to chronic wounds.^{43,45} The α -hydroxy and fatty acids that are released into the wound bed during the 3DES PM degradation process also enhance the lactate expression in the wound, which is understood to accelerate healing by promoting collagen deposition into the ECM and angiogenesis.^{46,47} Unpublished in vitro data demonstrated that 3DES PM reduced pH levels in isotonic phosphate buffered saline. A small pilot study is under development that will analyze the effect of 3DES PM on the wound microbiome and pH levels of DFUs.

The major limitation of this case series was that a small patient sample was evaluated without randomization in an uncontrolled environment. As a real-world and multicenter study, care proto-

cols varied among sites. Clinical judgement for applications and product availability varied at the sites and reflected the challenges and realities of physician discretion and patient care in daily clinical practice. For example, site #1 aimed to evaluate how the product contributed to healing, rather than if it fully closed wounds. Site #2 cautiously performed weekly debridement followed by weekly application of 3DES PM until healing was observed. Despite the variations in care and product use, all sites clearly demonstrated that 3DES PM has a positive and beneficial effect on the healing trajectory of refractory wounds. Also, the major advantage of conducting a real-world study is that a very sick and very heterogeneous patient population was enrolled with an average 4.4^{2,3} comorbidities per patient, many of which would have excluded the patients from enrollment in a controlled trial. Site #3 is a limb salvage wound clinic that attempts to treat

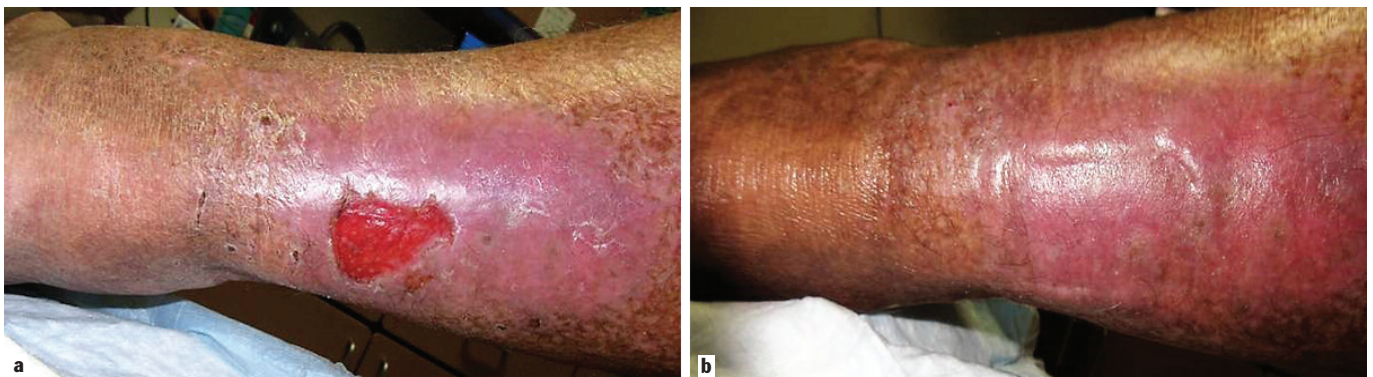

Figure 8a. A 79-year-old obese White male patient (subject 24) with diabetes, vascular insufficiency, and peripheral arterial disease presented to site #4 with four acute venous leg ulcers (all of one-week duration). Pictured here is wound 27 at baseline, which measured 9.44cm² on the right posterior lower extremity and was the largest of his wounds. **b)** Wound 27 on subject 24 is shown healed after 30 days of treatment with two applications of 3DES PM and standard of care alone.

the most severe cases as a final option before amputation, and so, the complexity of this study patient population must not be underestimated.

Furthermore, because this is a real-world study, all surviving patients continued to be under care at each site through November 2021. The sites confirmed that 40 wounds (80%, 7 additional wounds) eventually closed after their study participation ended at 12 weeks. For example, at site #4, two wounds healed with 3DESPM and standard of care alone at 104 and 168 days, respectively. Furthermore, at the time of writing, long-term healing durability has been suggested at site #3, where four patients did not experience recurrence after their study wounds healed in 2019.

CONCLUSION

In a real-world, complex patient population with severe comorbidities and heterogeneous wounds of various etiologies, 3DESPM appeared to have a beneficial effect on wound healing and most notably accelerated the stalled healing process and contributed to closure. In many wounds, the regeneration of strong and healthy tissue following treatment with 3DESPM was observed. To address the limitations of this current study, an RCT is under development that will evaluate 3DESPM on VLU, and multiple studies are under investigation that will evaluate the effect of 3DESPM on DFUs and acute surgical and trauma wounds. **STI**

ACKNOWLEDGMENTS

The authors would like to thank Dr. Marissa Carter (Strategic Solutions, Inc., Bozeman, Montana) for her assistance in data analysis and Jason McLeod (Bond Clinic P.A., Winter Haven, Florida) for his assistance in the data collection process.

AUTHORS' DISCLOSURES

Dr. Lambert received an honorarium from RenovoDerm for this study. Dr. Aviles was a paid consultant of RenovoDerm. Ms. Eckert was a paid consultant of Strategic Solutions for this study. Dr. Garoufalidis was a paid consultant for RenovoDerm. Dr. Schilling was a paid consultant for RenovoDerm. RenovoDerm sponsored this study.

REFERENCES

1. Nussbaum SR, Carter MJ, Fife CE, et al. An economic evaluation of the impact, cost, and Medicare policy implications of chronic nonhealing wounds. *Value Health* 2018;21(1):27–32.
2. Rice J, Desai U, Ristovska L, et al. Economic outcomes among Medicare patients receiving bioengineered cellular technologies for treatment of diabetic foot ulcers. *J Med Econ* 2015;18(8):586–95.
3. Sen CK. Human wounds and its burden: an updated compendium of estimates. *Adv Wound Care (New Rochelle)* 2019;8(2):39–48.
4. Steiner CA, Karaca Z, Moore BJ, et al. *Surgeries in Hospital-Based Ambulatory Surgery and Hospital Inpatient Settings 2014*. Agency for HealthCare Research and Quality, Rockville, MD: 2018.
5. Gao C, Zhang L, Wang J, et al. Electrospun nanofibers promote wound healing: theories, techniques, and perspectives. *J Mater Chem B* 2021;9(14):3106–30.
6. Graça MFP, de Melo-Diogo D, Correia IJ, et al. Electrospun asymmetric membranes as promising wound dressings: a review. *Pharmaceutics* 2021;13(2):183.
7. Ghomi ER, Khalili S, Khorasani SN, et al. Wound dressings: current advances and future directions. *J Appl Polym Sci* 2019;136(27):47738.
8. Dixit S, Baganizi DR, Sahu R, et al. Immunological challenges associated with artificial skin grafts: available solutions and stem cells in future design of synthetic skin. *J Biol Eng* 2017;11:49.
9. Dreifike MB, Jayasuriya AA, Jayasuriya AC. Current wound healing procedures and potential care. *Mater Sci Eng C* 2015;48:651–62.
10. Haddad AG, Giatsidis G, Orgill DP, et al. Skin substitutes and bioscaffolds: temporary and permanent coverage. *Clin Plast Surg* 2017;44(3):627–34.
11. Alghami ME, Saboor S, Amini-Nik S. Emerging innovative wound dressings. *Ann Biomed Eng* 2019;47(3):659–75.
12. Ontario Health (Quality). Skin substitutes for adults with diabetic foot ulcers and venous leg ulcers: a health technology assessment. *Ont Health Technol Assess Ser* 2021;21(7): 1–165.
13. Gordon AJ, Alfonso AR, Nicholson J, et al. Evidence for healing diabetic foot ulcers with biologic skin substitutes: a systematic review and meta-analysis. *Ann Plast Surg* 2019;83(4S Suppl 1):S31–44.
14. Tchero H, Herlin C, Bekara F, et al. Failure rates of artificial dermis products in treatment of diabetic foot ulcer: a systematic review and network meta-analysis. *Wound Repair Regen* 2017;25(4):691–6.
15. Dickinson LE, Gerecht S. Engineered biopolymeric scaffolds for chronic wound healing. *Front Physiol* 2016;7:341.
16. Miguel SP, Figueira DR, Simões D, et al. Electrospun polymeric nanofibers as wound dressings: a review. *Colloids Surf B Biointerfaces* 2018;169:60–71.
17. Akhmetova A, Heinz A. Electrospinning proteins for wound healing purposes: opportunities and challenges. *Pharmaceutics* 2020;13(1):4.
18. Azimi B, Maleki H, Zavagna L, et al. Bio-based electrospun fibers for wound healing. *J Funct Biomater* 2020;11(3):67.
19. Kai D, Liow SS, Loh XJ. Biodegradable polymers for electrospinning: towards biomedical applications. *Mater Sci Eng C Mater Biol Appl* 2014;45:659–70.
20. Lee KY, Jeong L, Kang YO, et al. Electrospinning of polysaccharides for regenerative medicine. *Adv Drug Deliv Rev* 2009;61(12):1020–32.
21. Boland ED, Matthews JA, Pawlowski KJ, et al. Electrospinning collagen and elastin: preliminary vascular tissue engineering. *Front Biosci* 2004;9:1422–32.
22. Mohd Hilmi AB, Hassan A, Halim AS. A bilayer engineered skin substitute for wound repair in an irradiation-impaired healing model on rat. *Adv Wound Care (New Rochelle)* 2015;4(5):312–20.
23. Stoddard RJ, Steger AL, Blakney AK, et al. In pursuit of functional electrospun materials for clinical applications in humans. *Theor Deliv* 2016;7:387–409.
24. Uppal R, Ramaswamy GN, Arnold C, et al. Hyaluronic acid nanofiber wound dressing—production, characterization, and in vivo behavior. *J Biomed Mater Res* 2011;97(1):20–9.
25. Mulholland EJ. Electrospun biomaterials in the treatment and prevention of scars in skin wound healing. *Front Bioeng Biotech* 2020;8:1–15.
26. Wijayarathne SM, Kannangara L. Safety and efficacy of electrospun polycarbonate-urethane vascular graft for early hemodialysis access: first clinical results in man. *JAVA* 2011;12:28–35.
27. Romeo A, Easley J, Regan D, et al. Rotator cuff repair using a bioresorbable nanofiber interposition scaffold: a biomechanical and histologic analysis in sheep. *J Shoulder Elbow Surg* 2022;31(2):402–12.
28. Lavery LA, Barnes SA, Keith MS, et al. Prediction of healing for postoperative diabetic foot wounds based on early wound area progression. *Diabetes Care* 2008;31(1):26–9.
29. Coerper S, Beckert S, Küper MA, et al. Fifty percent area reduction after 4 weeks of treatment is a reliable indicator for healing—analysis of a single-center cohort of 704 diabetic patients. *J Diabetes Complications* 2009;23(1):49–53.
30. Snyder RJ, Cardinal M, Dauphinée DM, et al. A post-hoc analysis of reduction in diabetic foot ulcer size at 4 weeks as a predictor of healing by 12 weeks. *Ostomy Wound Manage* 2010;56(3):44–50.
31. Massand S, Lewcun JA, LaRosa CA. Clinical and cost efficacy of advanced wound care matrices in the treatment of venous leg ulcers: a systematic review. *J Wound Care* 2021;30(7):553–61.
32. Barbul A, Gelly H, Masturzo A. The health economic impact of living cell tissue products in the treatment of chronic wounds: a retrospective analysis of Medicare claims data. *Adv Skin Wound Care* 2020;33(1):27–34.
33. Samsell B, McLean J, Cazzell S, et al. Health economics for treatment of diabetic foot ulcers: a cost-effectiveness analysis of eight skin substitutes. *J Wound Care* 2019;28(Sup9):S14–26.
34. Martinson M, Martinson N. A comparative analysis of skin substitutes used in the management of diabetic foot ulcers. *J Wound Care* 2016;25(Sup10):S8–17.
35. Zelen CM, Serena TE, Gould L, et al. Treatment of chronic diabetic lower extremity ulcers with advanced therapies: a prospective, randomised, controlled multi-centre comparative study examining clinical efficacy and cost. *Int Wound J* 2016;13:272–82.
36. Wissing TB, Bonito V, Bouten CVC, et al. Biomaterial-driven in situ cardiovascular tissue engineering—a multidisciplinary perspective. *NPJ Regen Med* 2017;2:18.
37. Lowery JL, Datta N, Rutledge GC. Effect of fiber diameter, pore size and seeding method on growth of human dermal fibroblasts in electrospun poly(epsilon-caprolactone) fibrous mats. *Biomaterials* 2010;31(3):491–504.
38. Fukunishi T, Best CA, Sugiura T, et al. Tissue-engineered small diameter arterial vascular grafts from cell-free nanofiber PCL/chitosan scaffolds in a sheep model. *PLoS One* 2016;11(7):e0158555.
39. Kalan LR, Brennan MB. The role of the microbiome in nonhealing diabetic wounds. *Ann N Y Acad Sci* 2019;1435(1):79–92.
40. Grice EA, Segre JA. Interaction of the microbiome with the innate immune response in chronic wounds. *Adv Exp Med Biol* 2012;946:55–68.
41. Mustoe TA, O'Shaughnessy K, Kloeters O. Chronic wound pathogenesis and current treatment strategies: a unifying hypothesis. *Plast Reconstr Surg* 2006;117(7 Suppl):355–41S.
42. Jones EM, Cochrane CA, Percival SL. The effect of pH on the extracellular matrix and biofilms. *Adv Wound Care (New Rochelle)* 2015;4(7):431–9.
43. Percival SL, McCarty S, Hunt JA, et al. The effects of pH on wound healing, biofilms, and antimicrobial efficacy. *Wound Repair Regen* 2014;22(2):174–86.
44. Nagoba BS, Suryawanshi NM, Wadher B, et al. Acidic environment and wound healing: a review. *Wounds* 2015;27(1):5–11.
45. Greener B, Hughes AA, Bannister NP, et al. Proteases and pH in chronic wounds. *J Wound Care* 2005;14(2):59–61.
46. Porporato PE, Payen VL, De Saedeleer CJ, et al. Lactate stimulates angiogenesis and accelerates the healing of superficial and ischemic wounds in mice. *Angiogenesis* 2012;15(4):581–92.
47. Traboldo O, Wagner S, Wicke C, et al. Lactate and oxygen constitute a fundamental regulatory mechanism in wound healing. *Wound Repair Regen* 2003;11(6):504–9.