


# The efficacy of a novel 3-D electrospun synthetic polymer matrix (3DESPM) on the management of difficult-to-heal wounds

C. Jake Lambert, Jr. MD, FACS, CWSP, Bond Clinic P.A., Winter Haven, FL; Frank Aviles, Jr., PT, CWS, FACCWS, CLT-LANA, ALM, AWCC, Natchitoches Regional Medical Center, Natchitoches, LA;

Kristen A. Eckert, MPhil, Strategic Solutions, Inc., Bozeman, MT; Matthew Garoufalis, DPM, FASPS, FACPM, CWS, Professional Foot Care Specialists, P.c., Chicago, IL; Richard A. Schilling, DPM, FACFAS, ABC Podiatry, Columbus, OH

## INTRODUCTION – A NOVEL 3D ELECTROSPUN SYNTHETIC POLYMER MATRIX (3DESPM)

Wound care is becoming a public health crisis in the wake of a rapidly aging population increasingly facing the toll of diabetes and obesity. Cost-effective treatments are urgently needed to facilitate closure in refractory wounds. Skin grafts, including cellular and/or tissue-based products, are widely used to treat difficult-to-heal wounds, but graft failure is a major concern, while the application of costly advanced wound dressings risks damaging the wound bed.<sup>1-6</sup> Recent systematic reviews of the use of skin grafts and substitutes on chronic wounds have found them effective to treat diabetic foot ulcers (DFUs),<sup>7-9</sup> but evidence for venous leg ulcers (VLUs) is inconclusive, mainly due to the small patient populations enrolled in trials.<sup>8</sup> A non-immunogenic, bioresorbable scaffold that promotes cellular activity and granulation, mimics the extracellular matrix (ECM), and manages free radicals to transition the chronic wound to the acute state has been considered the optimal skin substitute and wound dressing.<sup>1,10</sup>



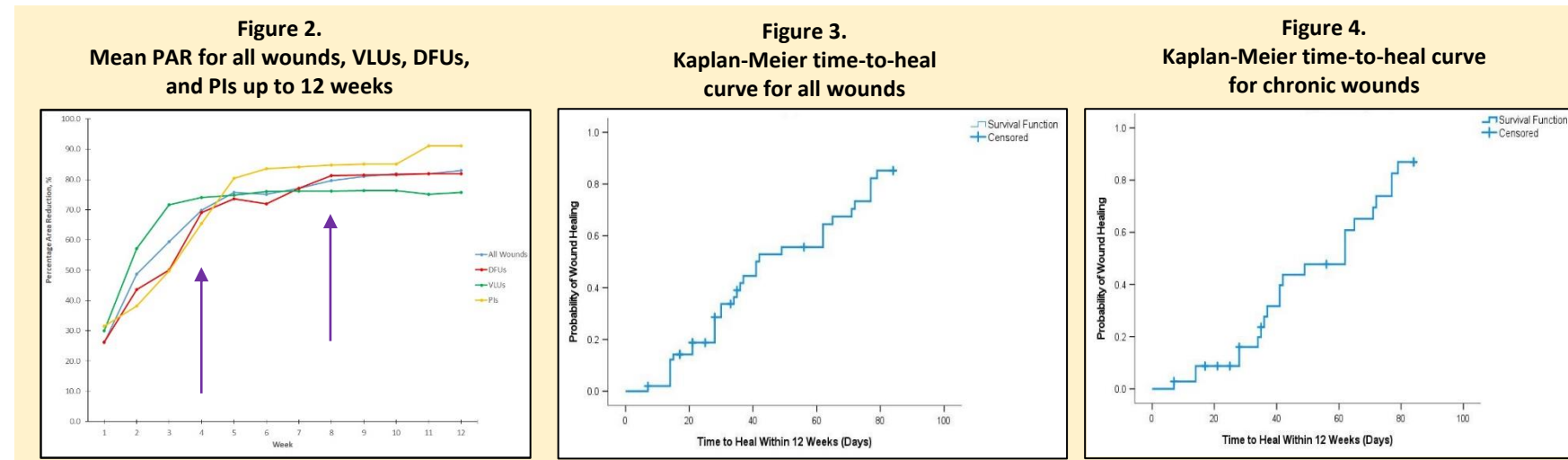
A novel 3-D electrospun synthetic polymer matrix (3DESPM, PHOENIX™ Wound Matrix, RenovoDerm®, Dublin, OH) is scientifically engineered to mimic native ECM to provide a multidimensional solution to wound healing. The 3DESPM microporous scaffold has fibers ranging 600–1,000 nm in diameter (Fig. 1) and acts as a stimulus to facilitate pro-regenerative cellular adhesion, infiltration, and proliferation for the tissue regeneration and repair of acute/chronic wounds and burns. Comprised of two bioresorbable synthetic polymers, Polyglycolide or poly(glycolic acid (PGA) and poly(L-lactide-co-caprolactone) (PLCL), 3DESPM naturally degrades into  $\alpha$ -hydroxy acids and fatty acids, which stimulate pro-regenerative cellular activity for wound healing. 3DESPM acts as a protective barrier, supporting a pro-healing wound environment, by enacting low pH and lactate mediated effects that address chronicity and sustained inflammation, helping to restore the healing process. 3DESPM demonstrated a reduction in pH from 7.4 to 4.75 within a 1-week period during an in vitro degradation test in isotonic PBS solution (unpublished). In this multicenter cases series, the efficacy of 3DESPM on the management of difficult-to-heal wounds of various etiologies on complex patients was evaluated.

## METHODS

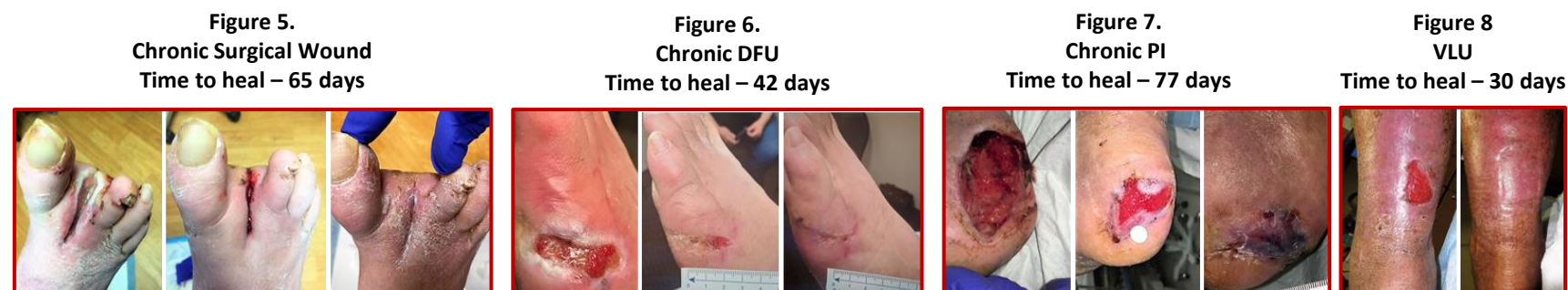This prospective case series took place at 4 sites of care. The primary endpoints were the percentage area reduction (PAR) in wound area at 4 and 8 weeks. Secondary endpoints included time to heal and the total proportion of healed wounds at 12 weeks. Patients with difficult-to-heal wounds, who had good nutritional management, demonstrated adequate perfusion and good blood flow based on palpable pulses and vascular studies, and had their hemoglobin A1C controlled (<10% to <13%) when presenting with diabetes were eligible for study inclusion. Standard of care included infection and vascular assessment/management, debridement, moist dressings, offloading for DFUs and pressure injuries (PIs), multilayer compression for VLUs, and an air mattress turning schedule for PIs. After applying 3DESPM, the providers rinsed the product and wound with sterile saline to facilitate the polymer degradation process, as necessary, backed the product with a nonadherent dressing, and applied a secondary dressing. Additional bandages were applied, as necessary, to bolster and protect the wound. 3DESPM was left on the wound until complete degradation was observed (7-14 days), or reapplied as clinically appropriate. Combination advanced therapies were utilized, per physician discretion.

## RESULTS

Thirty-eight patients [mean age: 64.3 years (SD: 17.6)] with 50 wounds (35 chronic, 70%) participated. The mean number of comorbidities per patient was 4.4 (2.3). All wounds were treated with 3DESPM; 38 (76%) completed the study. Twelve wounds (24%) received combination advanced therapy with 3DESPM. The mean PAR at 4 and 8 weeks was 67.6% (38%) and 80% (35%), respectively. The Mean PAR was similar for all wound types, with slightly higher reductions observed in PIs (Fig. 2).



Thirty-three wounds (66%) healed at 12 weeks. Four wounds (8%) healed with 3D ESPM combined with negative pressure wound therapy, hyperbaric oxygen therapy, and/or collagen dressings. Closure rates at 12 weeks were similar among all wound types and chronic wounds in this study (66% vs 63%). The mean time to heal was 49.0 days [95% Confidence Interval (CI): 41.3-56.7] for all wounds (Fig. 3) and 53.8 days (95% CI: 45.4-62.2) for chronic wounds (Fig. 4). Figures 5-8 depict examples of healed wounds over the course of the study.



## CONCLUSIONS

In a real-world, complex, and heterogeneous patient and wound population, treatment with 3DESPM resulted in an impressive mean baseline wound area reduction of 66% at 4 weeks postapplication, and the mean PAR increased to 80% by 8 weeks, suggesting the early healing effect of 3DESPM is efficacious and contributes to wound closure. The evaluation of 3DESPM on a larger patient population and in a controlled setting is pending.

### Study Highlights

- **Complex and very sick patients with difficult-to-heal wounds enrolled**
- **50 wounds of different etiologies were treated (70% chronic)**
- **Mean number of comorbidities per patient was 4.4**
- **Wounds were substantial in size with a mean baseline area of 10.2 cm<sup>2</sup>**
- **Acceleration of the stalled healing process confirmed**
- **Mean PAR at 4 and 8 weeks was 67.6% and 80%, respectively**
- **Times to heal were similar for all wounds healing on average in <8 weeks**
- **≤2 applications of 3DESPM were used to treat the majority of wounds (31/50, 62%)**

RENOVODERM

1. Graça MFP, de Melo-Diogo D, Correia IJ, Moreira AF. Electrospun asymmetric membranes as promising wound dressings: a review. *Pharmaceutics* 2021; 13(2): 183.; 2. Ghomi ER, Khalili S, Khorasani SN, et al. Wound dressings: current advances and future directions. *J Appl Polym Sci* 2019; 136(27): 47738.; 3. Dixit S, Baganizi DR, Sahu R, et al. Immunological challenges associated with artificial skin grafts: available solutions and stem cells in future design of synthetic skin. *J Biol Eng* 2017; 11: 49.; 4. Dreifke MB, Jayasuriya AA, Jayasuriya AC. Current wound healing procedures and potential care. *Mater Sci Eng C*. 2015; 48: 651–662.; 5. Haddad AG, Giatsidis G, Orgill DP, et al. Skin substitutes and bioscaffolds: temporary and permanent coverage. *Clin Plast Surg* 2017; 44(3): 627-634.; 6. Aljghami ME, Saboor S, Amini-Nik S. Emerging innovative wound dressings. *Ann Biomed Eng* 2019; 47(3): 659–675.; 7. Ontario Health (Quality). Skin substitutes for adults with diabetic foot ulcers and venous leg ulcers: a Health Technology Assessment. *Ont Health Technol Assess Ser* 2021; 21(7): 1–165.; 8. Gordon AJ, Alfonso AR, Nicholson J, Chiu ES. Evidence for healing diabetic foot ulcers with biologic skin substitutes: a systematic review and meta-analysis. *Ann Plast Surg* 2019; 83(4S Suppl 1): S31–S44.; 9. Tchoer H, Herlin C, Bekara F, Kangambega P, Sergiu J, Teot L. Failure rates of artificial dermis products in treatment of diabetic foot ulcer: a systematic review and network meta-analysis. *Wound Repair Regen* 2017; 25(4): 691–696.; 10. Dickinson LE, Gerecht S. Engineered biopolymeric scaffolds for chronic wound healing. *Front Physiol* 2016; 7: 341.